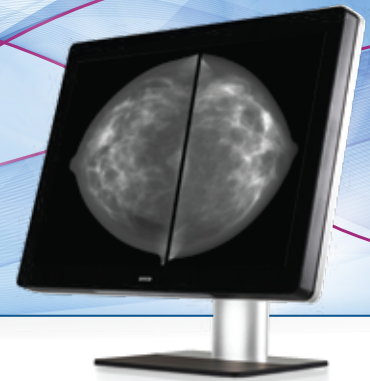

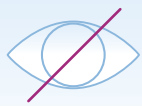3D Density Assessment

Clinically Proven for Digital Mammography and Digital Breast Tomosynthesis

Automated. Objective. Volumetric.



Experience the Benefits of VolparaDensity



Reproducible and objective results when compared to human assessment of breast density.



Consistent across manufacturers, models, and imaging modes. Compatible with most digital mammography and tomosynthesis units.

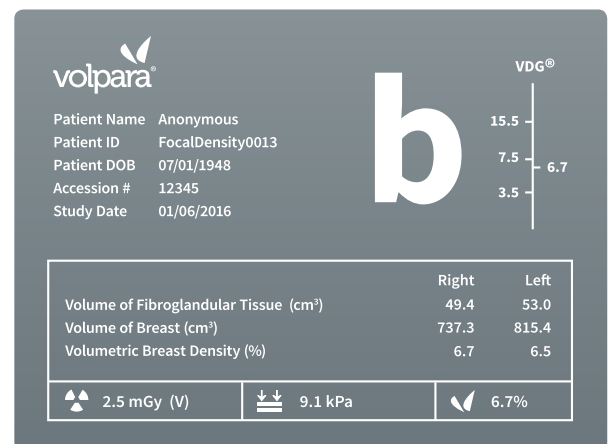


Immediate identification of women who may benefit from supplemental screening.



The only volumetric breast density (VBD%) assessment validated with the Tyrer-Cuzick 8 risk model.

Volpara®Density™ software uses the power of AI to assess breast density with clinically proven performance that offers real, actionable advantages. It provides a repeatable, consistent, and objective means of scoring breast density.



Volpara Scorecard

The Case for Automated Breast Density Assessment



4-6 Times
GREATER RISK¹

For women with dense breasts to develop breast cancer when compared to women with fatty breasts



30% Less
SENSITIVITY²

In mammographic cancer detection for women with dense breasts when compared to women with fatty breasts

AND YET... VISUAL DENSITY ASSESSMENT
Is Not Always Consistent³

57%
Inter-reader agreement



77%
Intra-reader agreement

Thoroughly Validated

 **100+** Peer-Reviewed Articles

VolparaDensity has been strongly associated with

- Risk of interval cancers^{4,5,6}
- Risk of developing breast cancer^{7,8,9}

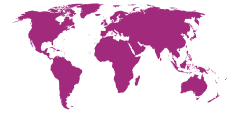Simple and Quick

VolparaDensity processes every screening mammogram and produces a Volpara scorecard that appears on the radiologist's or technologist's workstation, streamlining reporting and supplemental screening discussions with the patient.

Key Measurements

<p>Volpara Density Grade (VDG)</p>	<ul style="list-style-type: none"> • Correlates with BI-RADS Atlas 5th (or 4th) Edition breast composition categories
<p>Volumetric Breast Density (VBD%)</p>	<ul style="list-style-type: none"> • Enables easy, objective triage for greater clinical flexibility • Strongly correlates with the sensitivity of mammography • An important risk factor in the Tyrer-Cuzick 8 risk model

For Those Women Who Benefit Most



Referring physicians and insurers demand justification for supplemental screening. Objective, science-based evidence of high breast density is now a necessity when triaging women to supplemental screening.

Effective Triage Saves Money

Guiding a woman with dense breasts to supplemental imaging while she's still in the facility for her annual mammogram saves the cost of scheduling an additional appointment and an extra trip for the woman.

Join Us along with



Millions

of Women Around the World

Say "YES" to the Benchmark in Volumetric Density Assessment.

Used to analyze the breast density of millions of women around the world, VolparaDensity is an essential component for any breast imaging department.

To see how VolparaDensity can support your breast screening program, contact your Volpara Solutions representative for a live demonstration, or visit www.volparasolutions.com.

volparasolutions™

Contact us to learn more:

info@volparasolutions.com
support@volparasolutions.com

AUS 1800.370.623
EUROPE +44 203.051.1029
NZ 0800.444.148
US +1 855.607.0478
REST OF WORLD +64 4.499.6029

volparasolutions.com

BI-RADS® is a registered trademark of the American College of Radiology

References:

- Boyd et. al. N Engl J Med 2007; 356, 227
- Carney et. al. Ann Intern Med 2003;138(3):168-75
- Irshad et. al. AJR 2016;207:1366-1371
- van Gils. European Congress of Radiology, March 2-6, 2016, Vienna, Austria. European Institute for Biomedical Imaging Research Session 1 [A-225].
- <https://cordis.europa.eu/project/rcn/106433/reporting/en>
- Destounis et al. Radiological Society of North America 2015 Scientific Assembly and Annual Meeting, November 29 – December 4, 2015, Chicago IL. <http://archive.rsna.org/2015/15017085.html>
- Eng et al. Breast Cancer Res 2014;21(13):4124-32 DOI 10.1186/s13058-014-0439-1
- Brandt et al. Cancer Epidemiol Biomarkers Prev 2014; 23(9):1764-72. DOI: 10.1158/1055-9965.EPI-13-1219
- Park et al. Ann Surg Oncol 2014;21(13):4124-32. DOI 10.1245/s10434-014-3832-1

